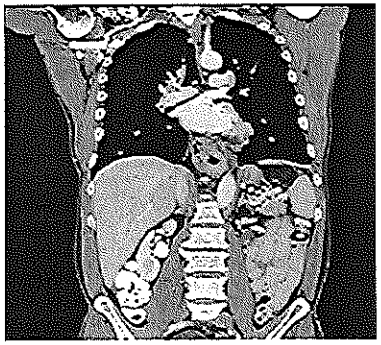

Anatomia

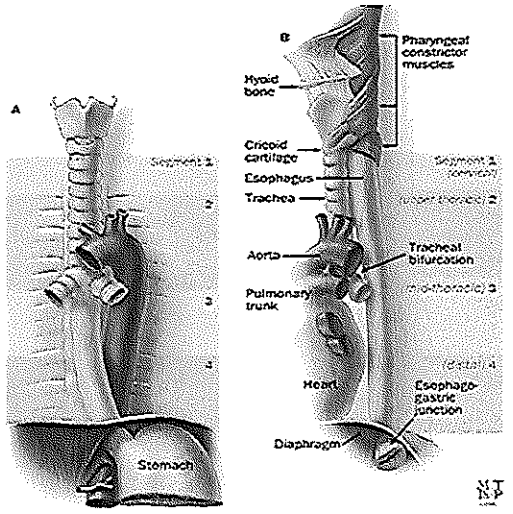

The Esophageal Wall

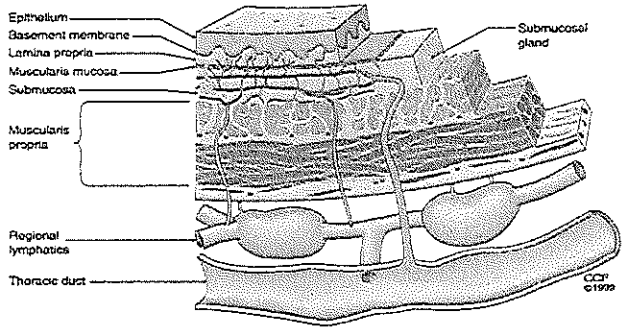

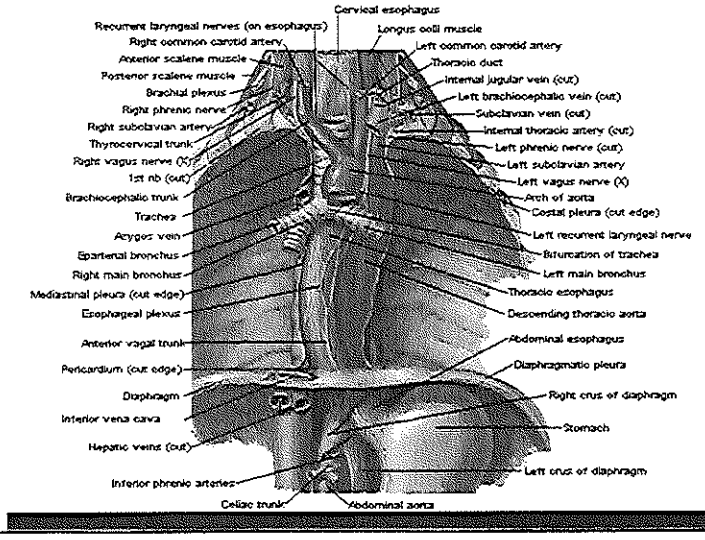

Giunto Esofago-Cardiale

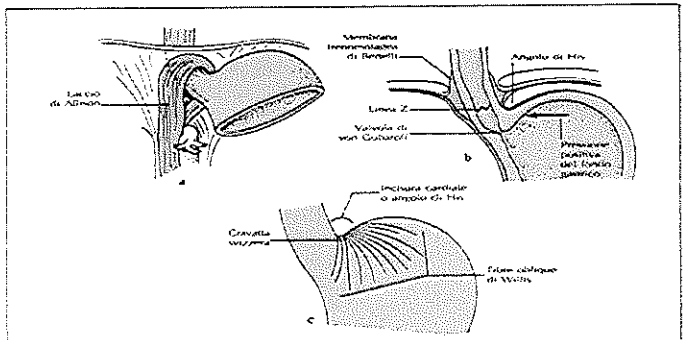

Fig. 7.3. *Strutture anatomiche che contribuiscono al mantenimento del tono della sfintere esofageo inferiore. (a) Rapporti tra il giunto esofago-gastrico ed il pilastro destro del diaframma (Taccio di Allison); (b) effetti della distensione del fondo gastrico sulla lunghezza addominale dell'esofago (o di His, N nota anche la presenza della "linea Z" e l'anello formato dal legamento sospensore della membrana trasversale con l'esofago; (c) contributo delle fibre muscolari di Willis e di Helvetius (considerate "cravatta stretta") al mantenimento di un angolo di His normale.*

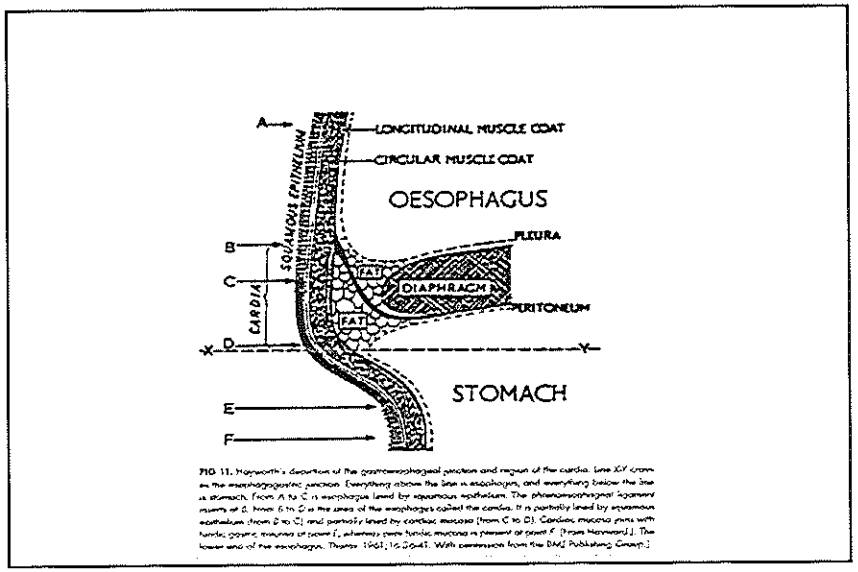

FIG 11. Hayworth's description of the gastroesophageal junction and region of the cardia. Line X-Y (from A to the mucosa) is the gastroesophageal junction. Everything above the line is esophagus, and everything below the line is stomach. From A to C is esophagus lined by squamous epithelium. The phrenicoesophageal ligament inserts at D. From D to C is the area of the esophagus called the cardia. It is partially lined by squamous epithelium (from D to C) and partially lined by cardiac mucosa (from C to D). Cardiac mucosa pairs with fundic gastric mucosa at point E, whereas pure fundic mucosa is present at point F. [From Hayworth J.]. The lower end of the esophagus. Thorax 1961; 16:30-41. With permission from the BMJ Publishing Group.]

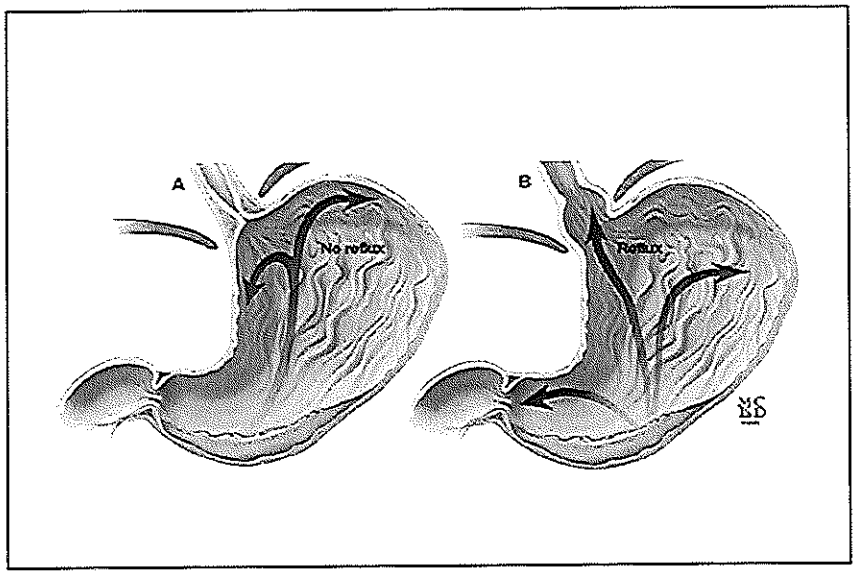

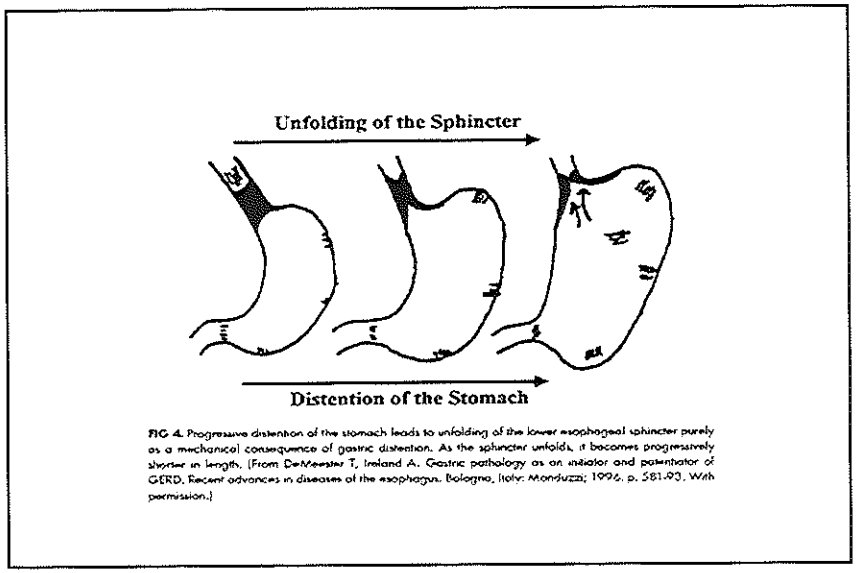

FIG 4. Progressive distention of the stomach leads to unfolding of the lower esophageal sphincter purely as a mechanical consequence of gastric distention. As the sphincter unfolds, it becomes progressively shorter in length. (From DeMeester T, Ireland A. Gastric pathology as an initiator and potentiator of GERD. Recent advances in diseases of the esophagus. Bologna, Italy: Monduzzi; 1996. p. 581-93. With permission.)

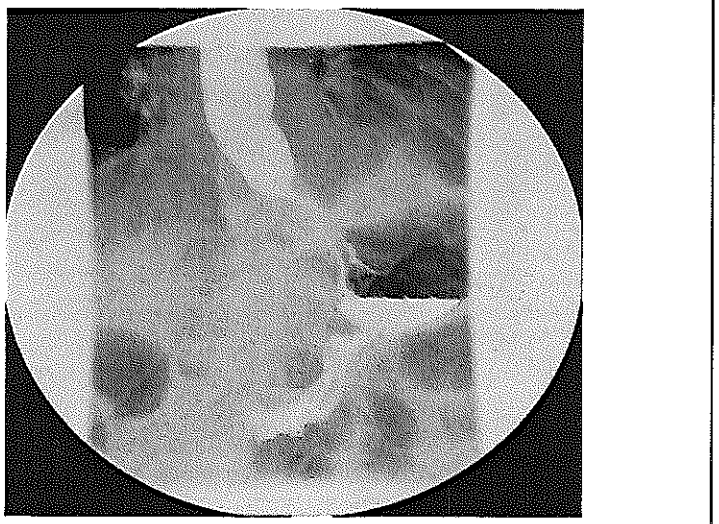

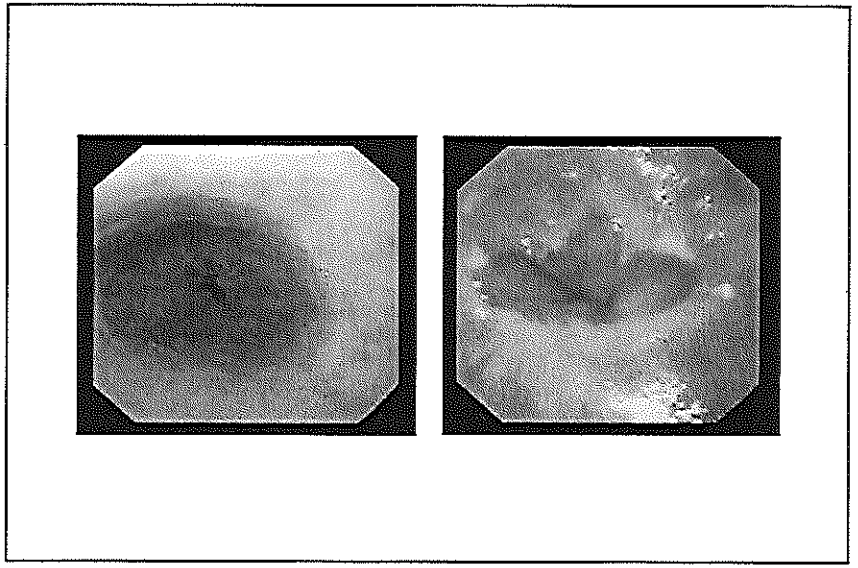

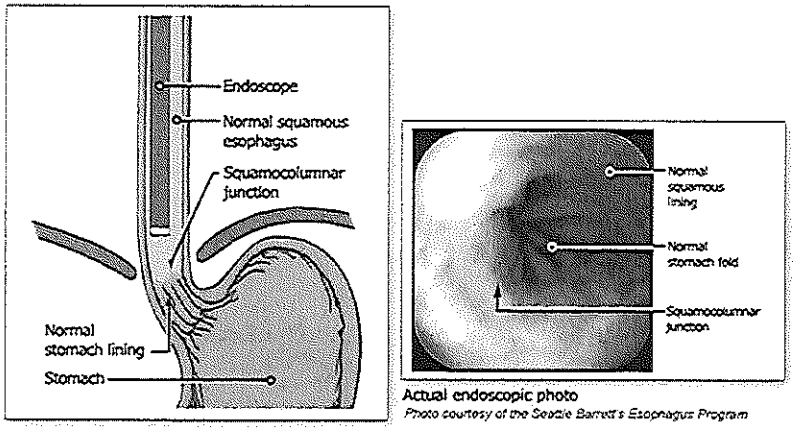
Endoscope
Normal squamous esophagus
Squamocolumnar junction
Normal stomach lining
Stomach
Normal squamous lining
Normal stomach fold
Squamocolumnar junction
Actual endoscopic photo
Photo courtesy of the Seattle Barrett's Esophagus Program

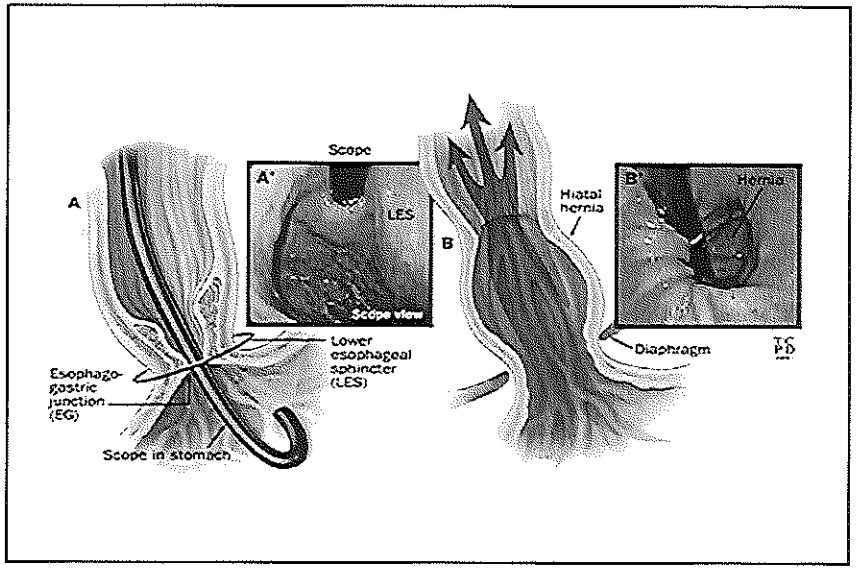
Scope
A
LES
Scope view
Lower esophageal sphincter (LES)
Esophago-gastric junction (EG)
Scope in stomach
B
Hiatal hernia
Hernia
Diaphragm

Istologia

-Carcinoma Squamoso

-Adenocarcinoma

Epidemiologia

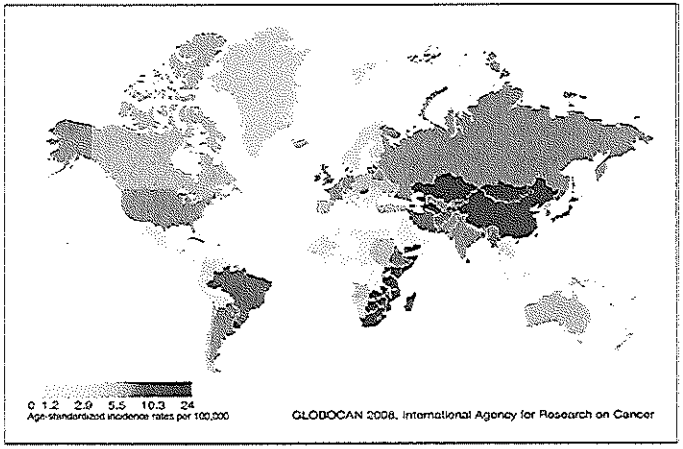

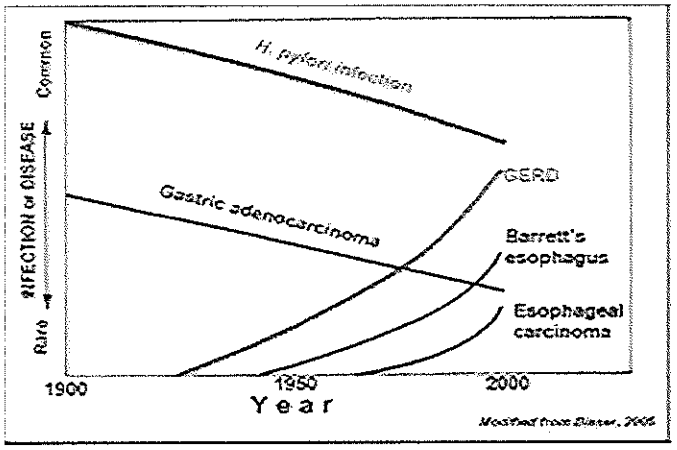

Eziologia

-Carcinoma Squamoso

-Irritazione cronica dell'esofago

-Deficit nutrizionali

-Condizioni predisponenti
- -Acalasia
- -Ingestione da caustici
- -Diverticoli esofagei
- -Infezioni da HPV
- -Sindrome di Plummer-Vinson
- -Tilosi

Eziologia

-Adenocarcinoma

-Reflusso Gastro-Esofageo

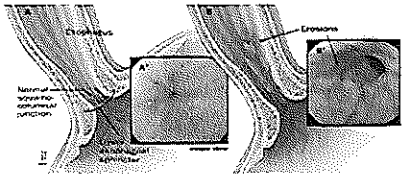

Eziologia

-Adenocarcinoma

-Reflusso Gastro-Esofageo

-Esofago di Barrett

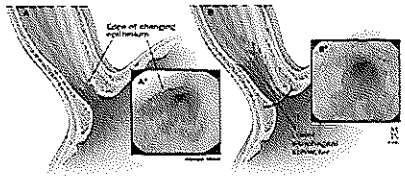

Eziologia

-Adenocarcinoma

-Reflusso Gastro-Esofageo

-Esofago di Barrett

-Obesità

Esofago di Barrett

ASA 2011

Any extent of metaplastic columnar epithelium that predisposes to cancer replaces the normal squamous epithelium that normally lines the distal oesophagus. The [illegible] oesophagus presently should be used only for patients who have intestinal metaplasia in the oesophagus.

Proposed British 2013

Barrett's oesophagus is defined as an oesophagus in which any portion of the normal distal squamous epithelial lining has been replaced by metaplastic columnar epithelium, which is **clearly visible endoscopically** above the gastro-oesophageal junction and **confirmed histopathologically** from oesophageal biopsies

The Barrett's Prague C&M Criteria

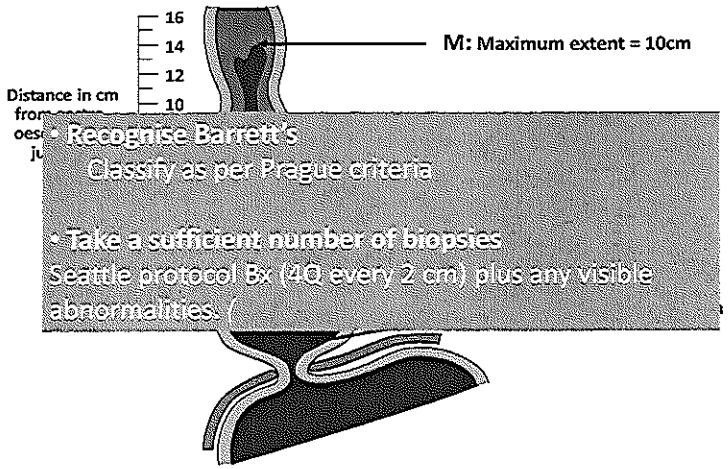

- Recognise Barrett's
  Classify as per Prague criteria
- Take a sufficient number of biopsies
  Seattle protocol Bx (4Q every 2 cm) plus any visible abnormalities. (



Growing consensus

- Do not need goblet cells to diagnose BE
- Cardiac mucosa in BE is intestinalised
- Does Fundic mucosa ever occur in BE? UK – yes, USA- no

- Intestinal Metaplasia > cancer risk *(Bhat 2011, Gatenby 2009)*
- Correlation > the length of Barrett's > risk of cancer
- Visible lesions considered malignant unless proven otherwise

Esofago di Barrett e Adenocarcinoma

-GERD è patologia frequente

-in caso di GERD, 1 su 10 sviluppa Esofago di Barrett

-in caso di Esofago di Barrett, <1% sviluppa Adenocarcinoma

-Esofago di Barrett spesso asintimatico (1 su 3)

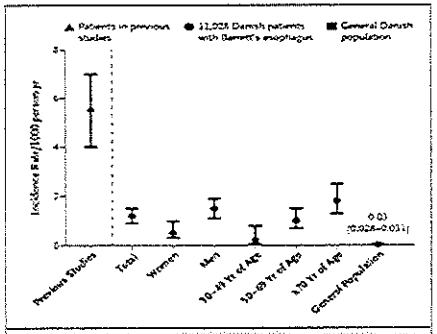

Figure 2. Incidence Rates of Esophageal Adenocarcinoma.
Incidence rates of esophageal adenocarcinoma are shown in a cohort of 11,028 Danish patients with Barrett's esophagus, as compared with mean incidence rates in the Danish general population and with mean incidence rates from previous international studies. Bars indicate 95% confidence intervals.

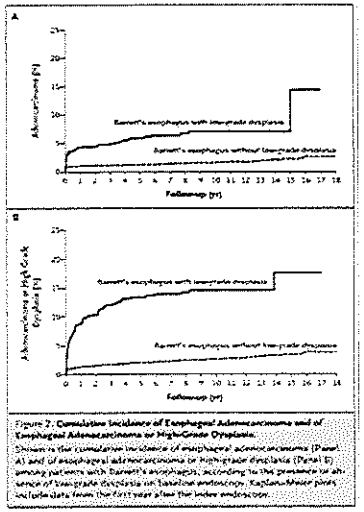

Figure 3. Cumulative Incidence of Esophageal Adenocarcinoma and of Esophageal Adenocarcinoma or High-Grade Dysplasia.
Shown is the cumulative incidence of esophageal adenocarcinoma (Panel A) and of esophageal adenocarcinoma or high-grade dysplasia (Panel B) among patients with Barrett's esophagus, according to the presence or absence of low-grade dysplasia on baseline endoscopy. Kaplan–Meier plots include data from the first year after the index endoscopy.

Esofago di Barrett

-Età > 40-45 anni

-Ernia jatale

-Lunga storia di GERD

Esofago di Barrett

-Età > 40-45 anni

-Ernia jatale

-Lunga storia di GERD



Esofago di Barrett e lesioni visibili

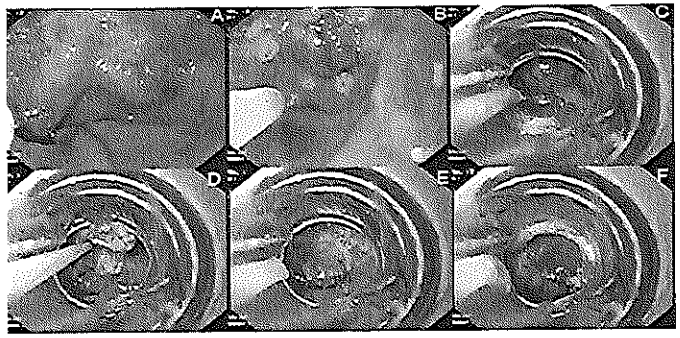

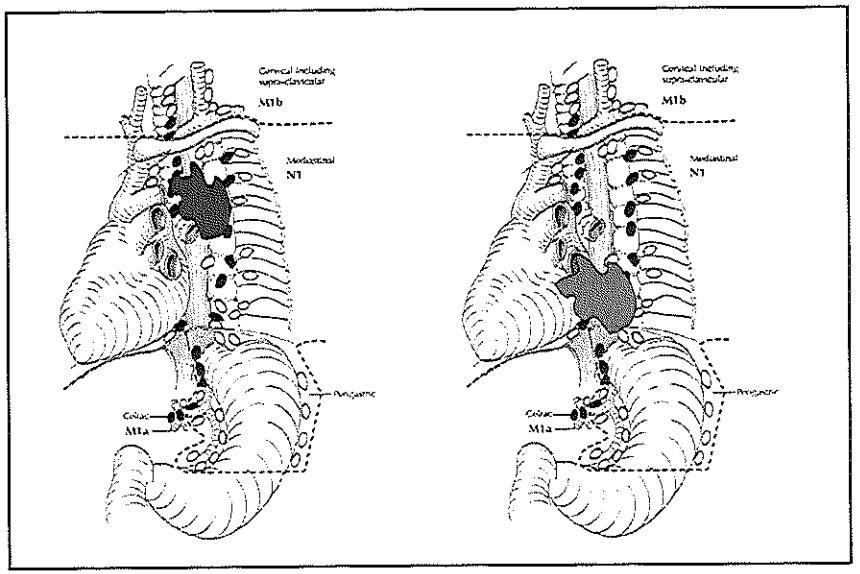

Sintomatologia

-Spesso ASSENTE nei tumori precoci

-Sintomi da interessamento esofageo e locoregionale
- -Disfagia
- -Perdita di peso
- -Tosse e rigurgito
- -Odinofagia
- -Vomito
- -Emorragia digestiva
- -Dolore
- -Disfonia
- -Singhiozzo

-Sintomi da interessamento sistemico

Diagnosi

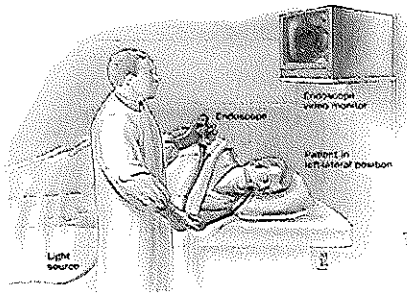

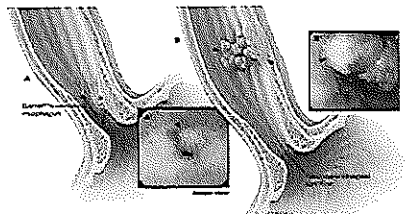

Stadiazione

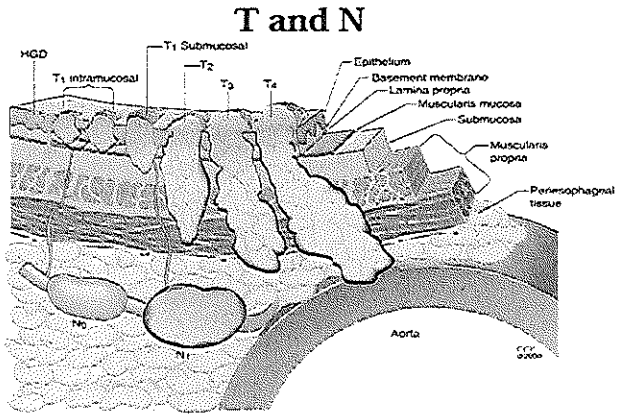

Stadiazione

-Giudizio di operabilità
- -TC torace-addome
- -PET TC
- -(Scintigrafia ossea)
- -Laparoscopia

-Giudizio resecabilità
- -EGDS
- -EUS
- -Broncoscopia
- -TC torace-addome
- -(Tubo digerente prime vie)

Operabilità

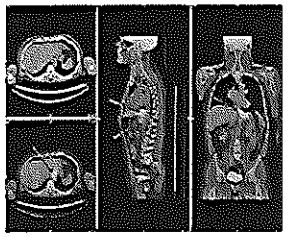

SI

Operabilità

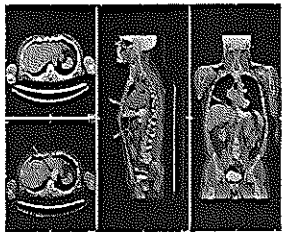

SI

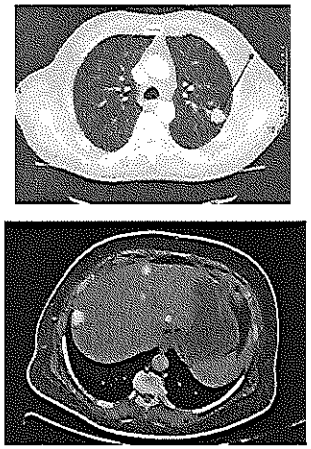

NO

Resecabilità

EUS

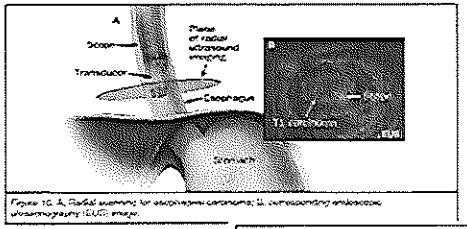

Figure 18. A, Radial scanning for esophageal carcinoma; B, corresponding endoscopic ultrasonography (EUS) image.

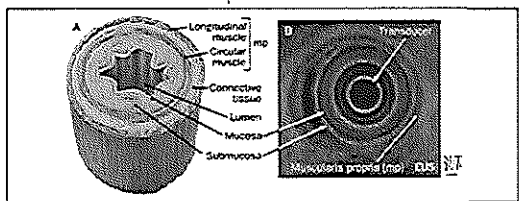

Figure 19. A, Normal anatomy of the esophageal wall; B, endoscopic ultrasonography (EUS) image.

EUS

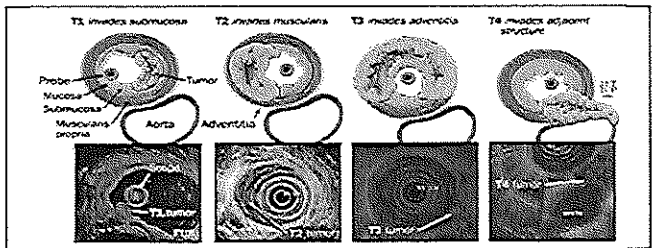

Figure 19. Esophageal carcinoma staging progression from T1 to T4 with corresponding endoscopic ultrasonography images.

EUS - FNA



Figure 20. A, Technique of fine needle aspiration (FNA); B, corresponding endoscopic ultrasonography image.

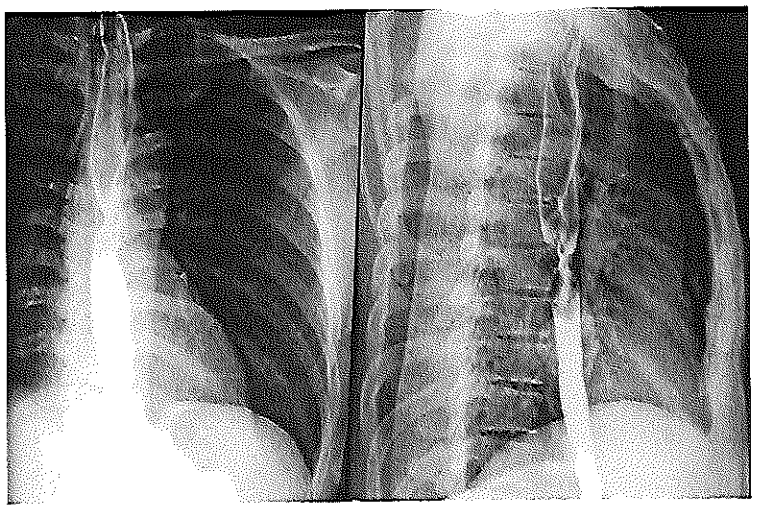

Trattamento

-Potenzialmente curativo
- -Resezione endoscopica
- -Chirurgia
- -Trattamento multimodale

-Palliativo
- -Trattamento endoscopico
- -RT
- -CHT
- -CRT

Resezione endoscopica

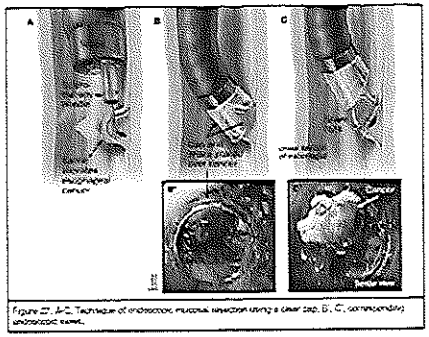

Chirurgia

-Esofagectomia in 2 tempi

-Esofagectomia in 3 tempi

-Esofagectomia trans-jatale

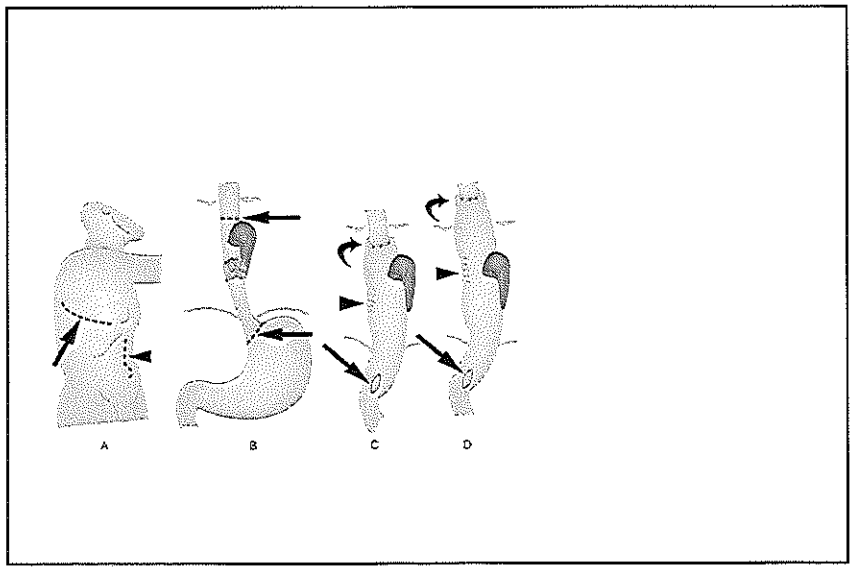

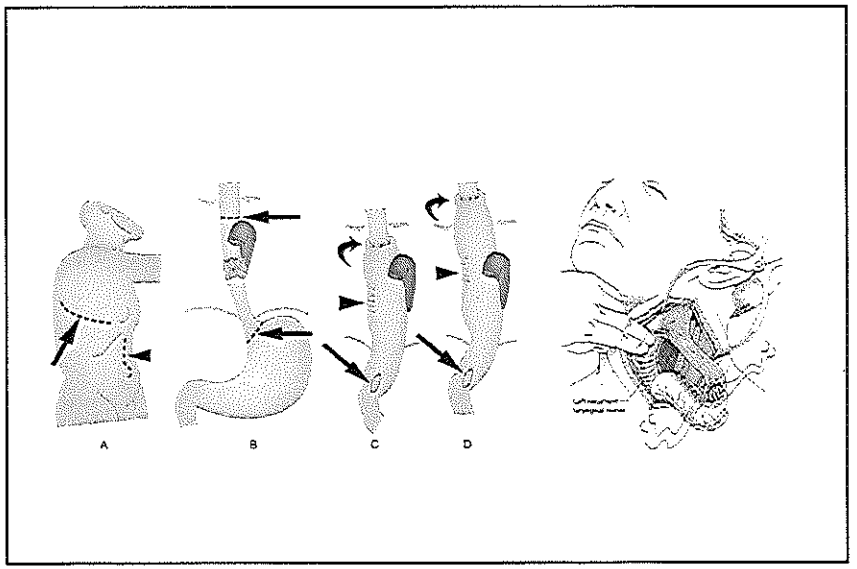

Ricostruzione

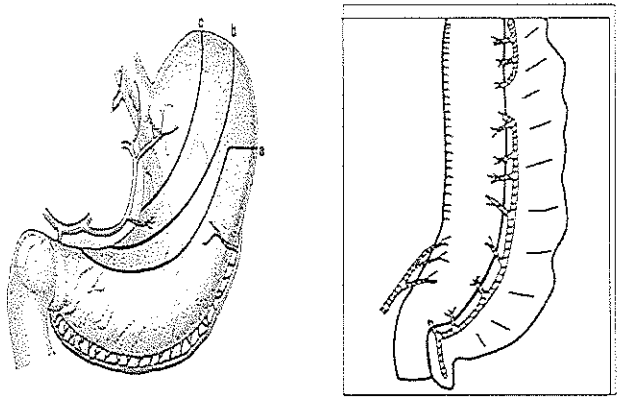

Palliazione endoscopica

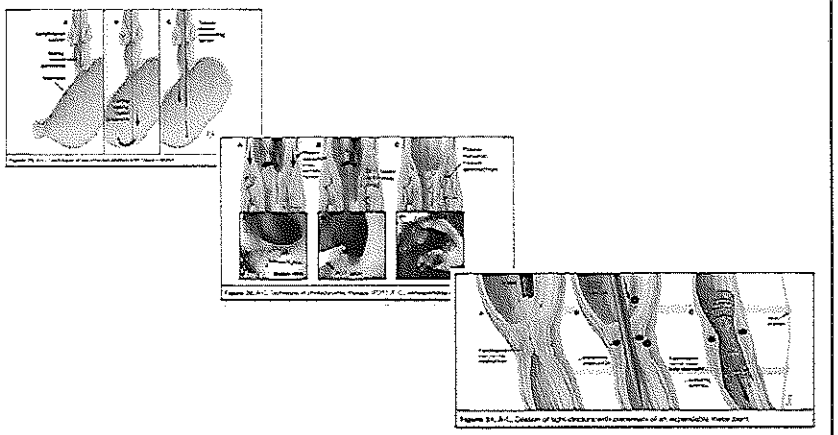

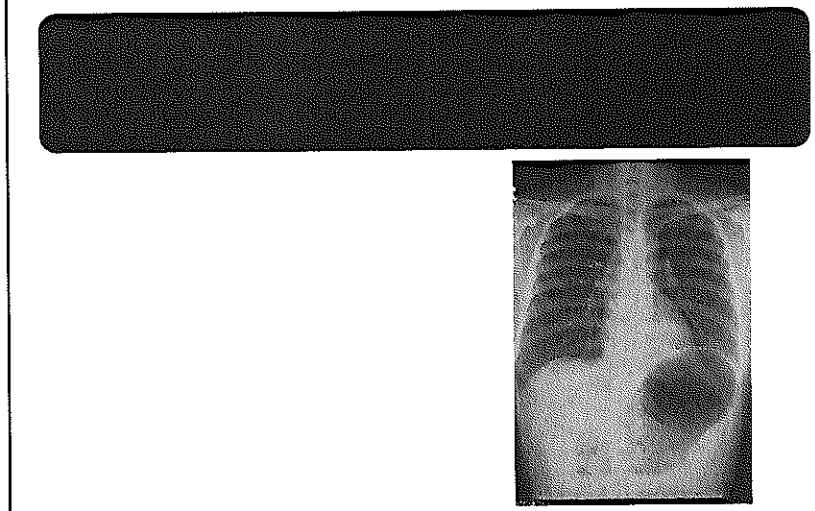

Anatomia

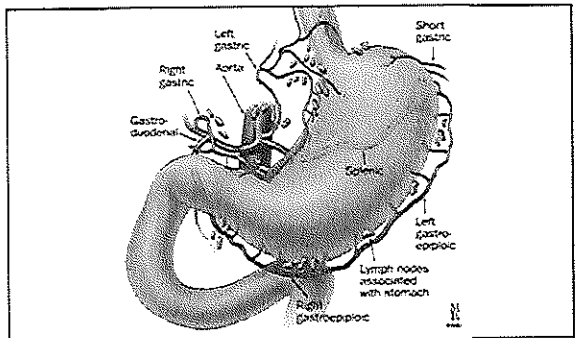

Figure 7. Normal external anatomy of the stomach with arteries and lymph nodes.

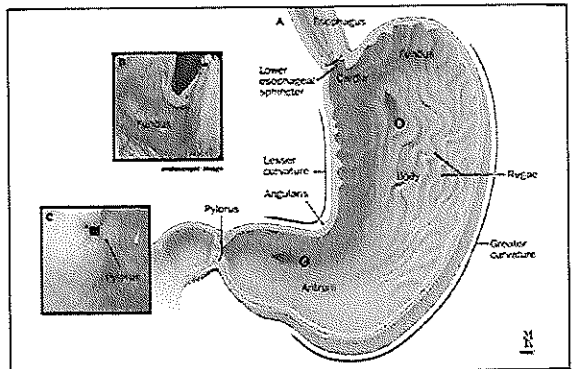

Figure 6. A. Normal internal anatomy of the stomach; B, C, endoscopic views.

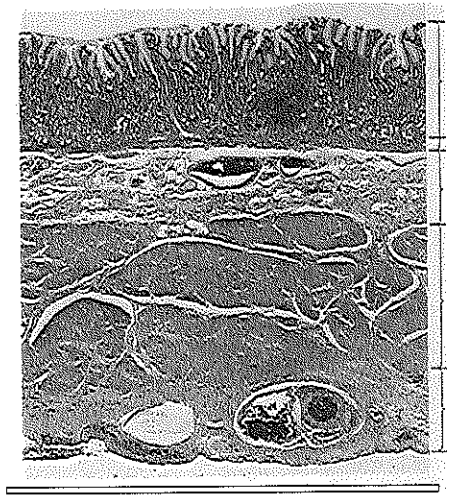

Epidemiologia

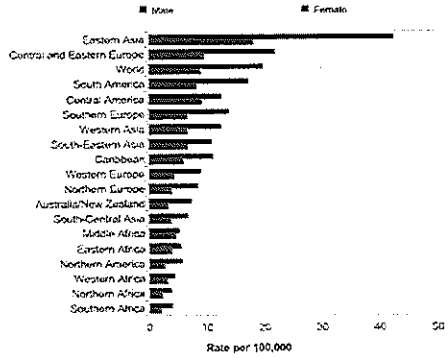

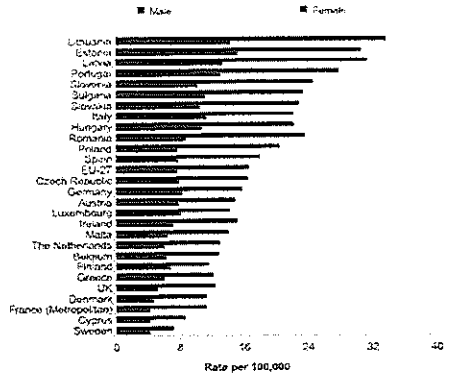

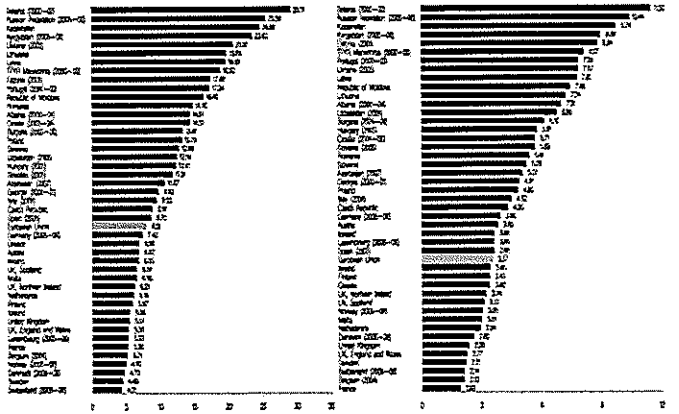

FIGURE 1. Overall age-standardized (world population) death certification rates from gastric cancer per 100,000 inhabitants, in the European Union (highlighted) and selected European countries, for the period 2005 to 2007 (unless otherwise specified in parentheses).

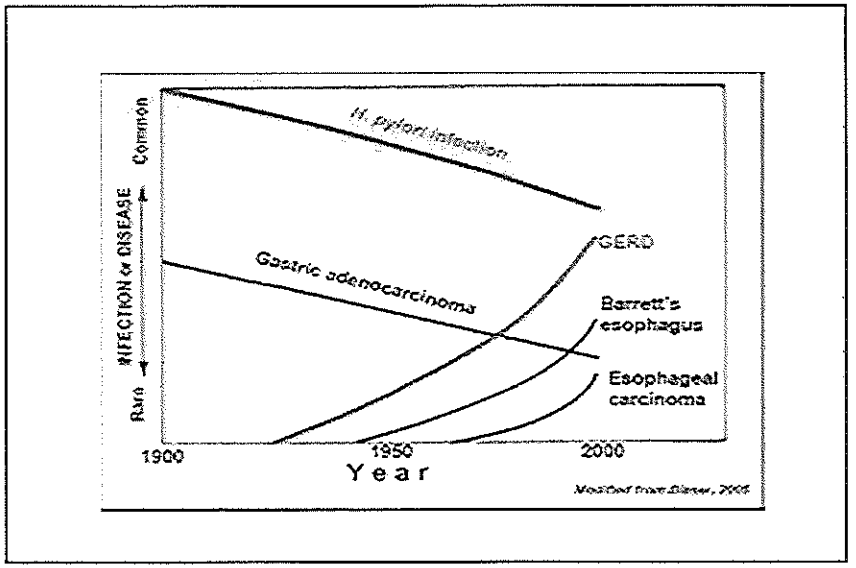

Risk factors of gastric cancer

1. **Dietary factors:** salty food
2. **Atrophic gastritis**

'atrophy-metaplasia-dysplasia-carcinoma sequence' (Correa P, 1988)

3. **Intestinal metaplasia**
4. ***Helicobacter pylori* infection**
5. **Familial history**

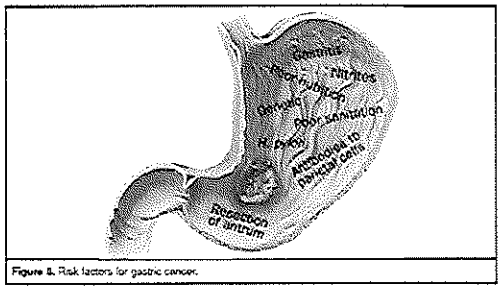

Figure 8. Risk factors for gastric cancer.

Helicobacter pylori infection

- Class I carcinogen for gastric cancer
- Seroprevalence of H. pylori in Korea:
  80% (in 1980s) → 67% (in 1990s)
- H. pylori is one of the important risk factors
  for the development of GC in Korea
  → OR 1.82 by one case-control study

Kim HS et al, Korean J Gastroenterol 1999
Chang WK et al, J Gastroenterol 2001

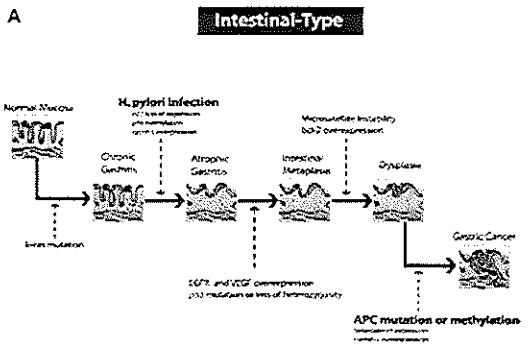

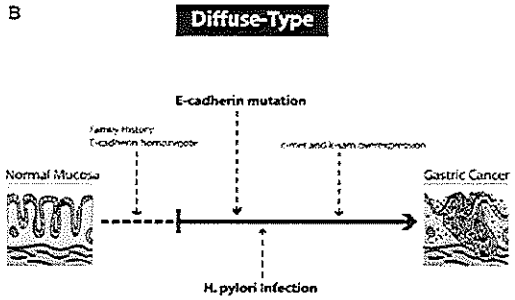

Hereditary Diffuse Gastric Cancer



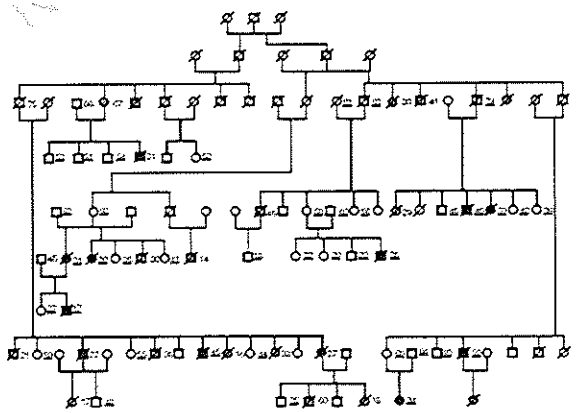

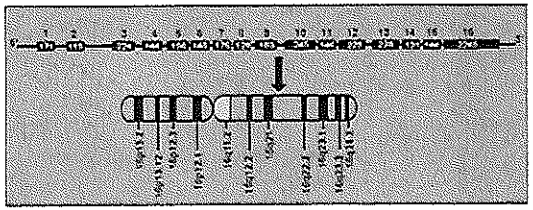

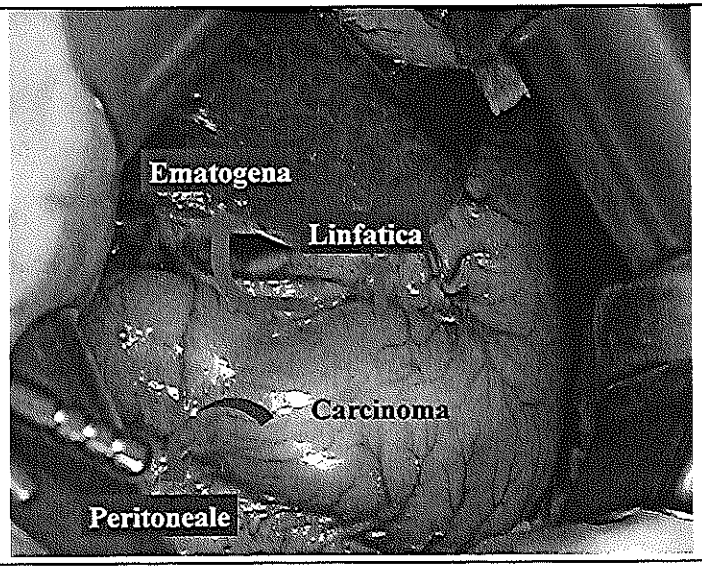

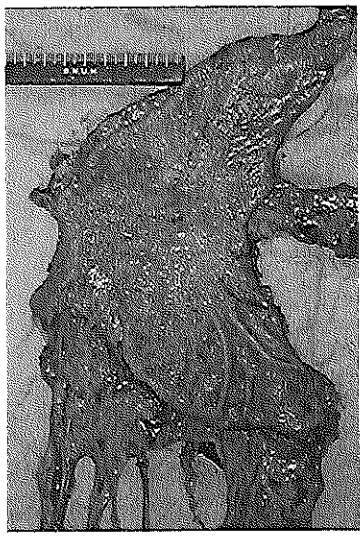

m/0 Ia

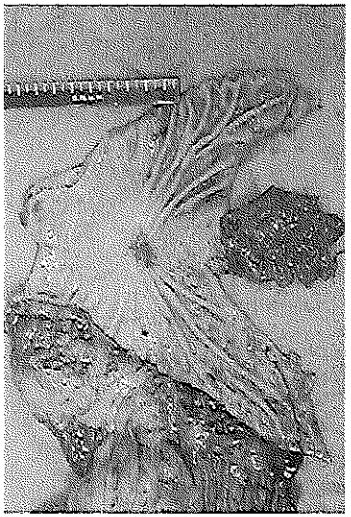

m/1 Ib

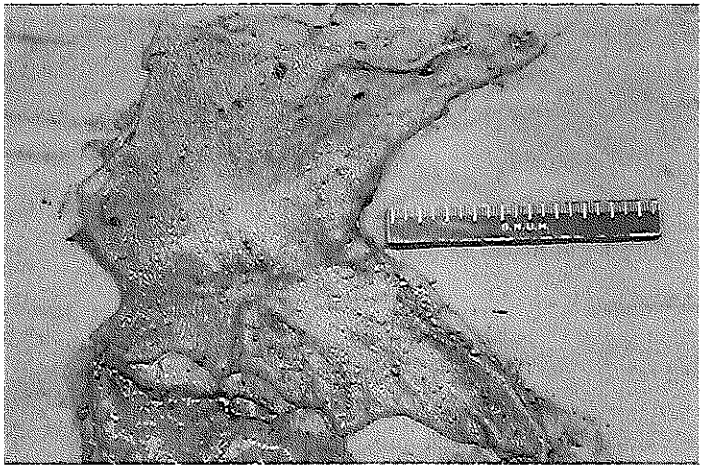

sm/0 Ia



om/2 II

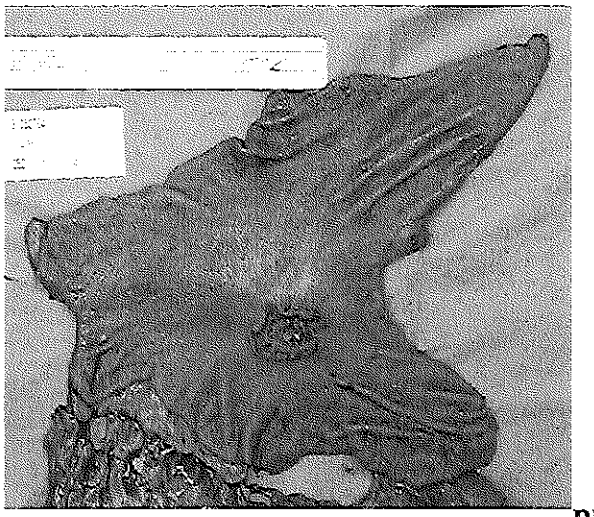

pm/0 Ib

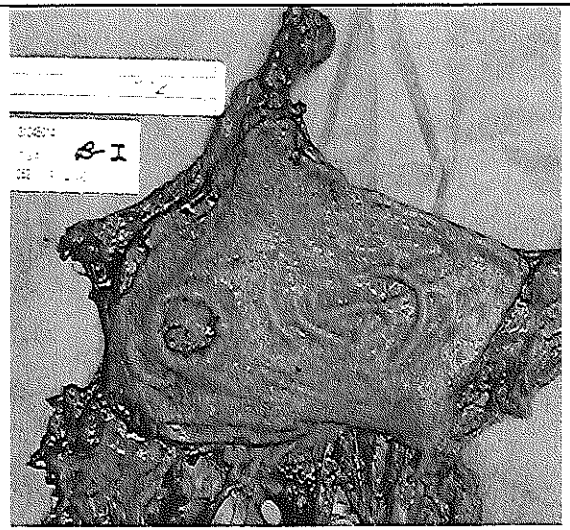

om/2 II

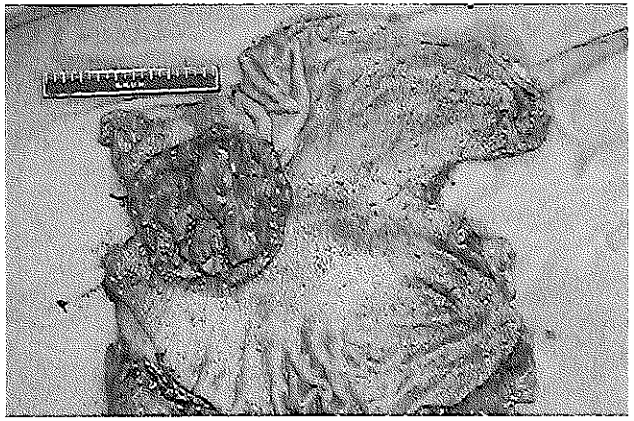

ss/0 Ib

s/9 IIIb

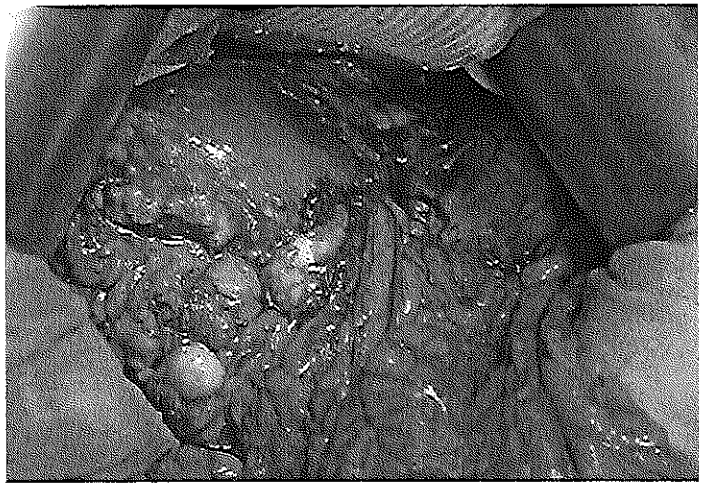

Gastric carcinoma

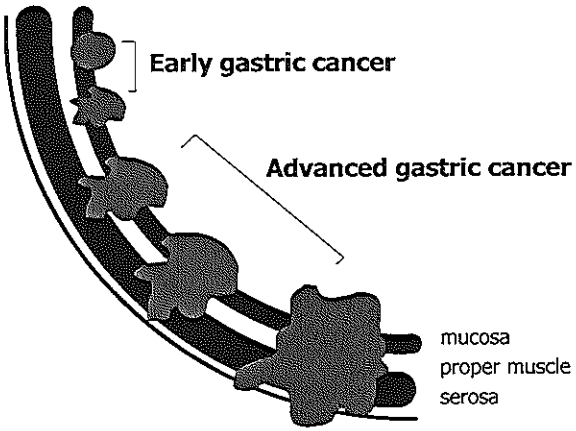

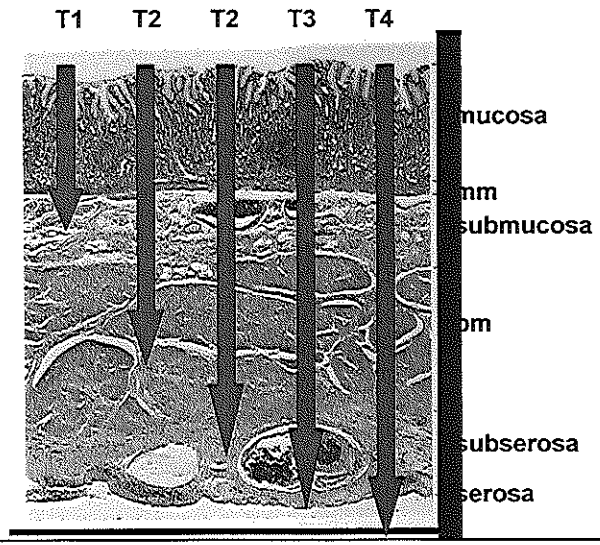

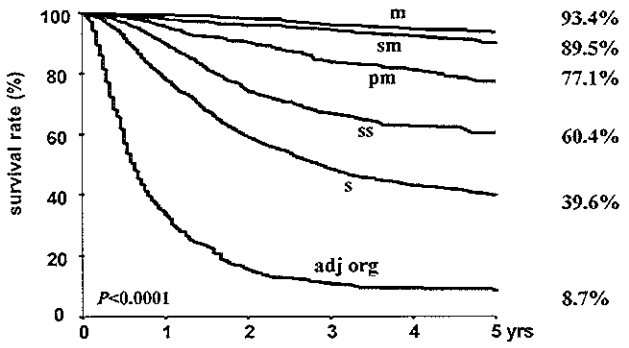

Survival curves according to the depth of invasion (T stage)

Istologia

-Tipo Intestinale

-Tipo Diffuso

Diagnosi

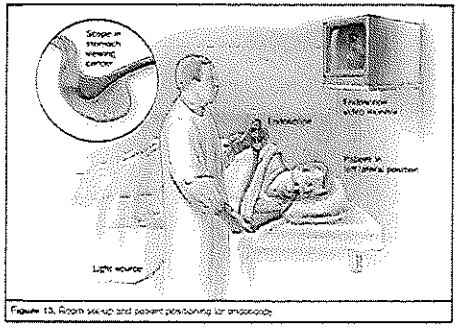

Stadiazione

-Giudizio di operabilità
- -TC torace-addome
- -PET TC
- -Laparoscopia

-Giudizio resecabilità/ Estensione dell'exeresi/ Trattamenti multimodali
- -EGDS
- -EUS
- -TC torace-addome
- -Laparoscopia
- -(Tubo digerente prime vie)

EGC treatment

- **EMR/ ESD**
- **Surgery**

EGC treatment

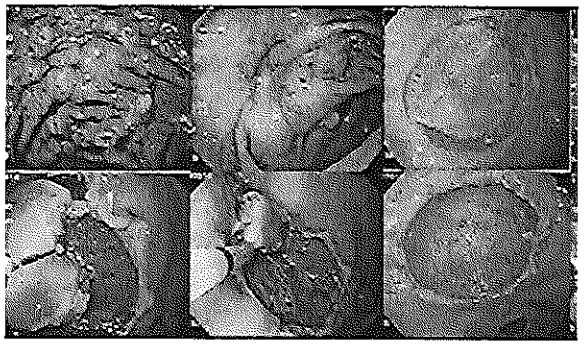

EGC treatment

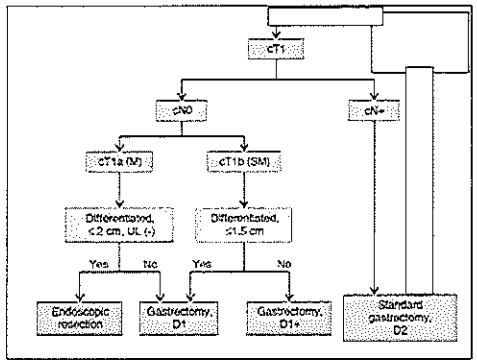

EGC treatment



Lymphatics of stomach

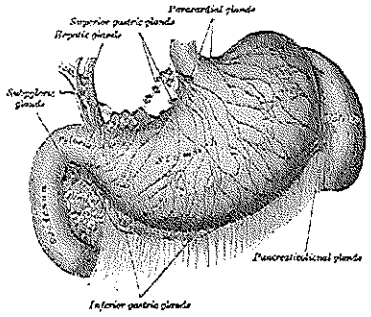

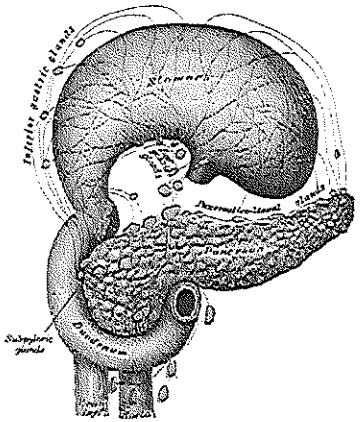

Henry Gray. Anatomy of the Human Body

F/24

CC. Melena
PI. 1yr epigas

Hb: 6.4 Tra

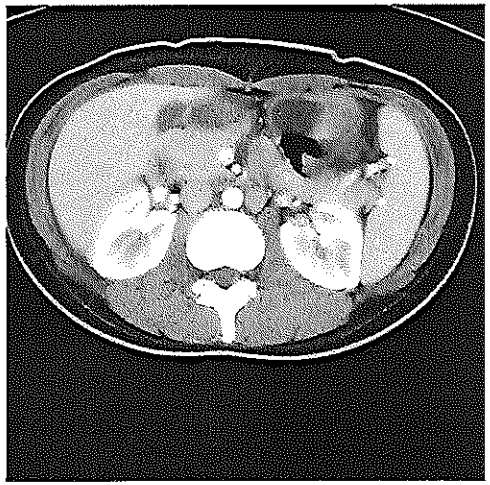

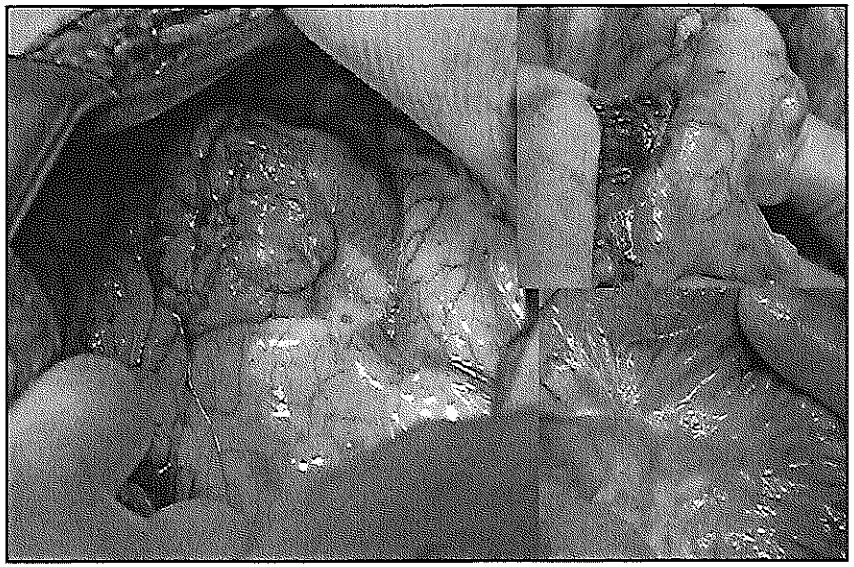

M/67

CC. Melena
PI. 3mo epigastr[redacted]

Hb: 7.2 Tranfu[redacted]

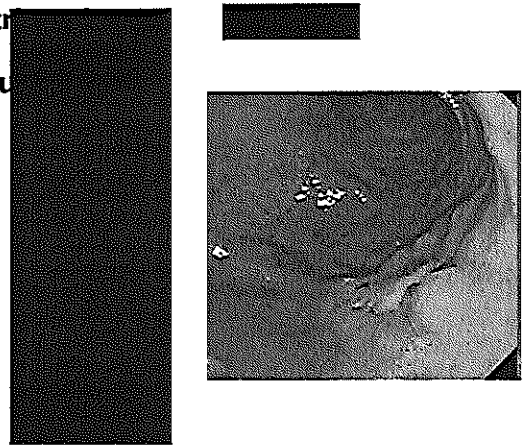

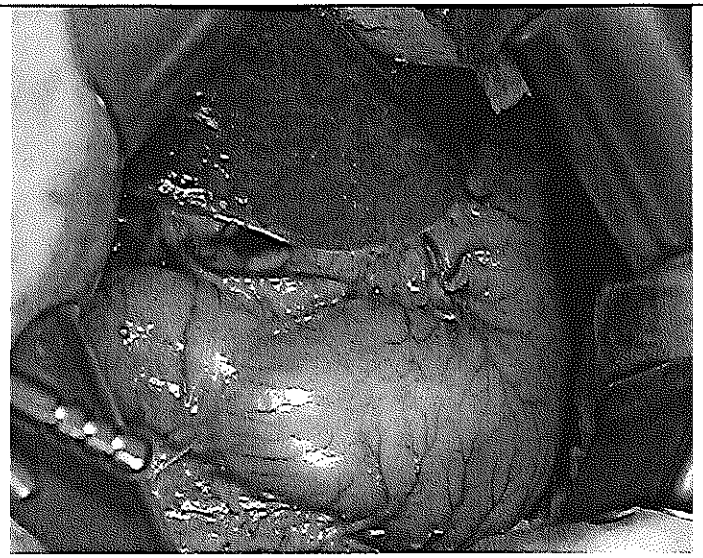

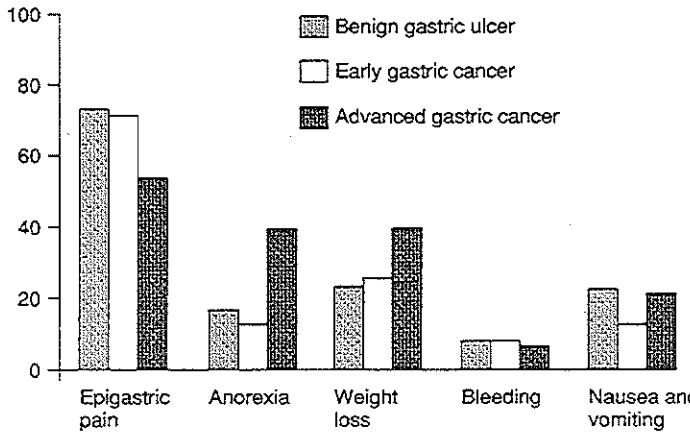

Oxford Text of Surgery

Symptoms of gastric cancer patients

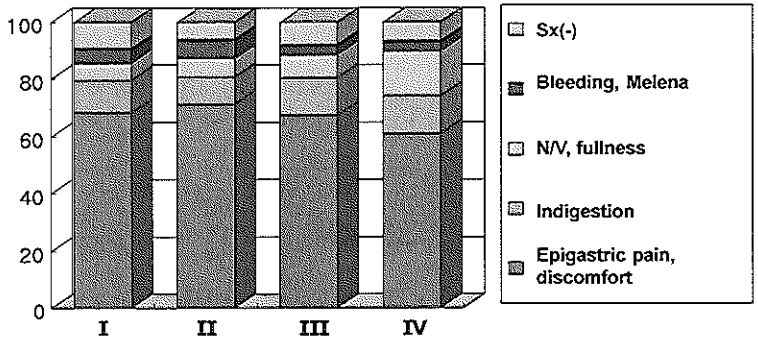

Choi MG, Lee JH, Park KJ, **Yang HK (Corresponding author)**, Park JG, Lee KU, Choe KJ, Kim JP. J Korean Surg Soc 1999;57(4):514-522

1999, Dept. of Surgery, SNUH

Endoscopic screening

Gastric cancer detected by endoscopy screening:

19 / 2501 (0.76%)

Stage	no.	(%)
I	15	(78.9)
II	1	(5.3)
III	1	(5.3)
IV	2	(10.5)
Total	19	

SNUH Health promotion center (2001)

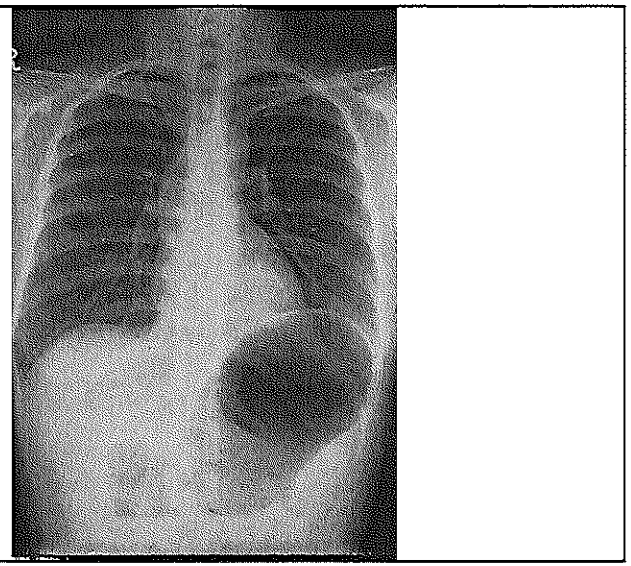

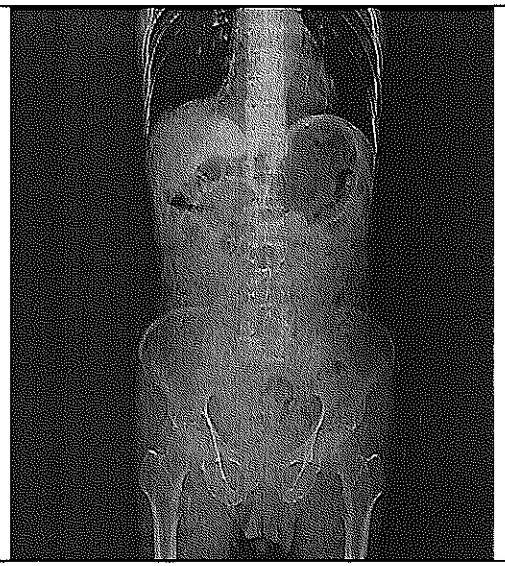

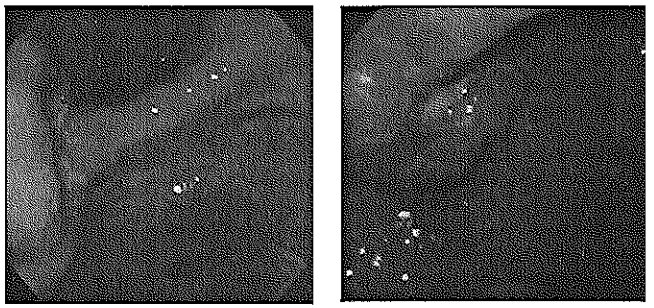

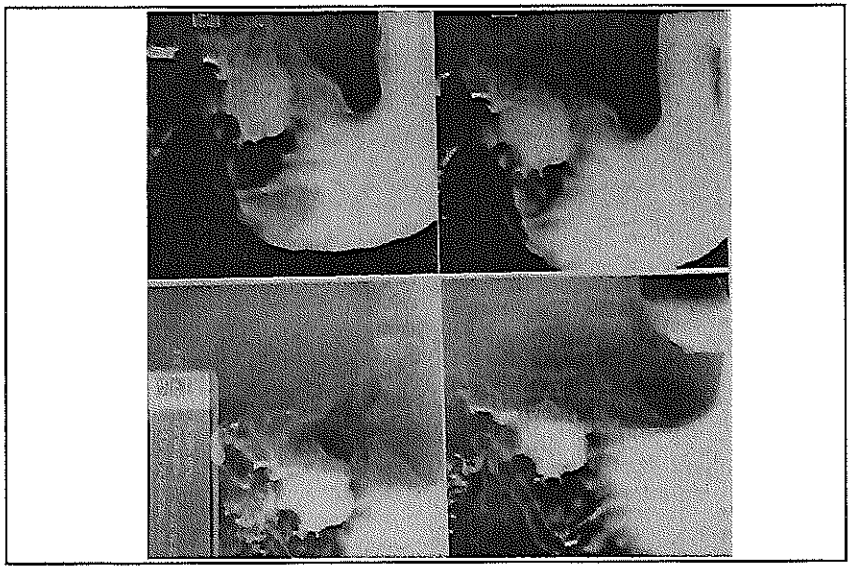

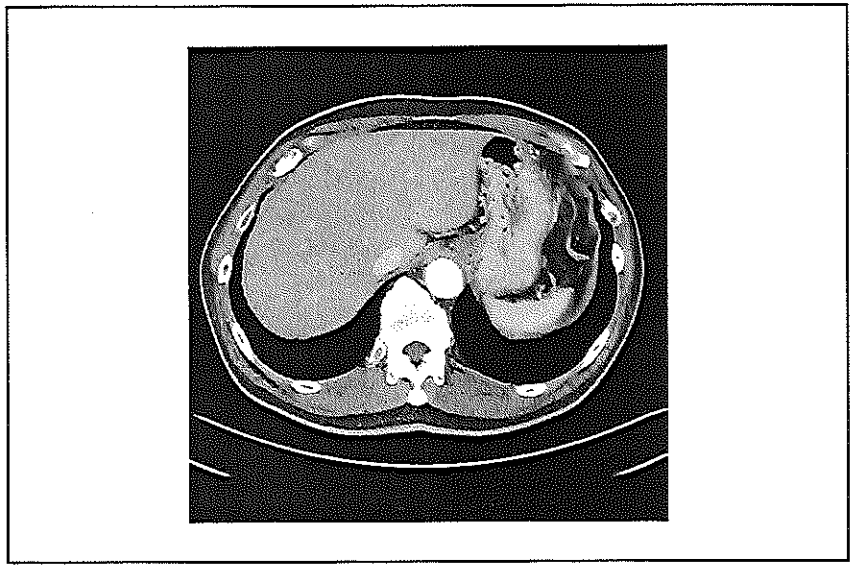

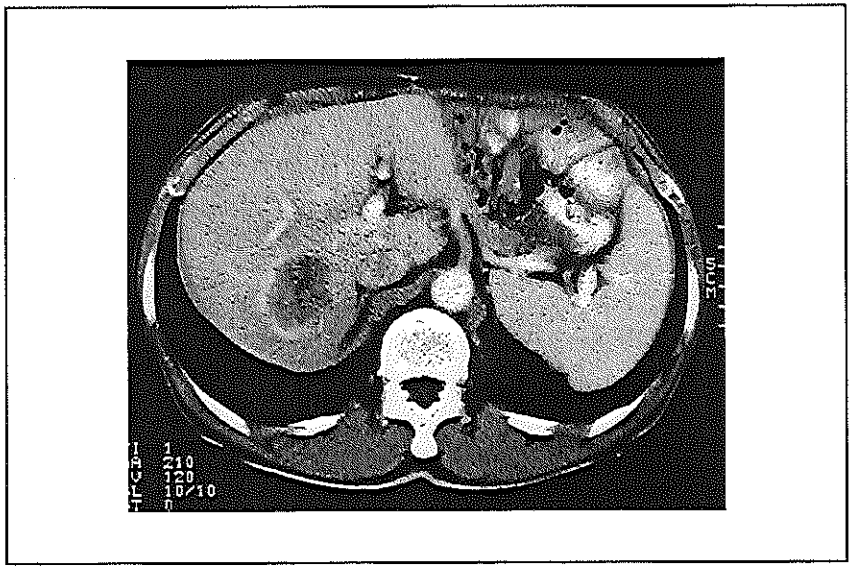
1
210
120
10/10

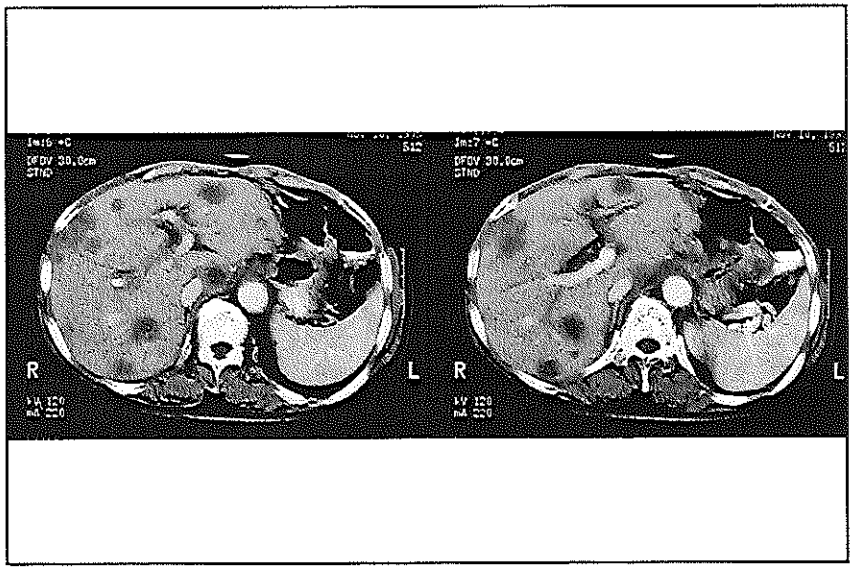
R
L
R
L

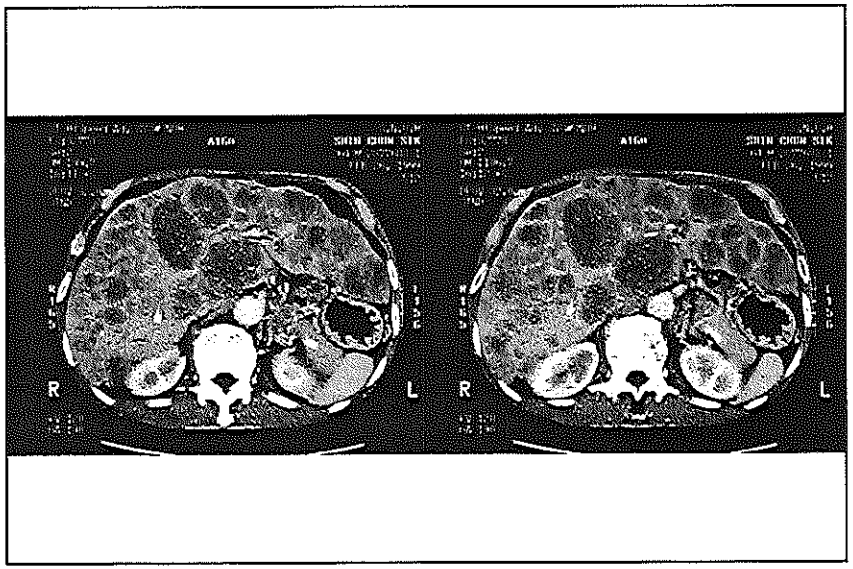
R
L
R
L

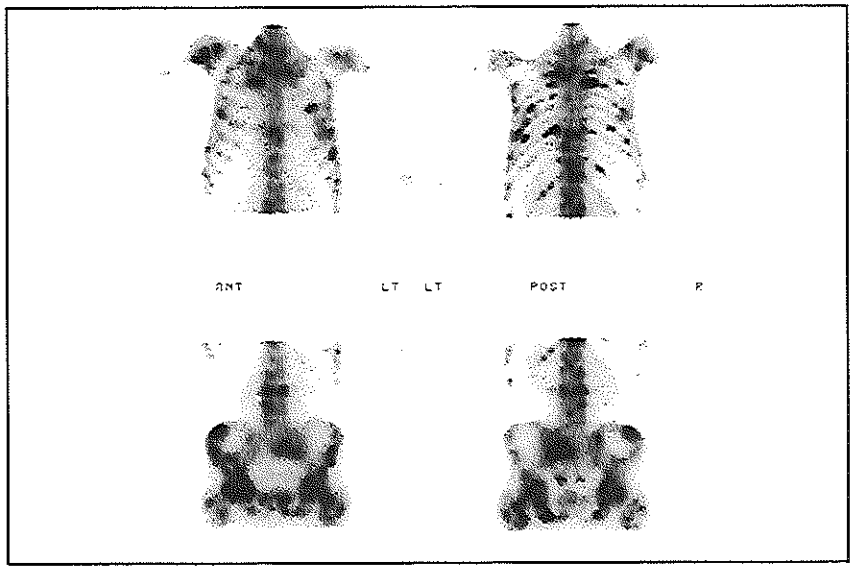
ANT
LT
LT
POST
R

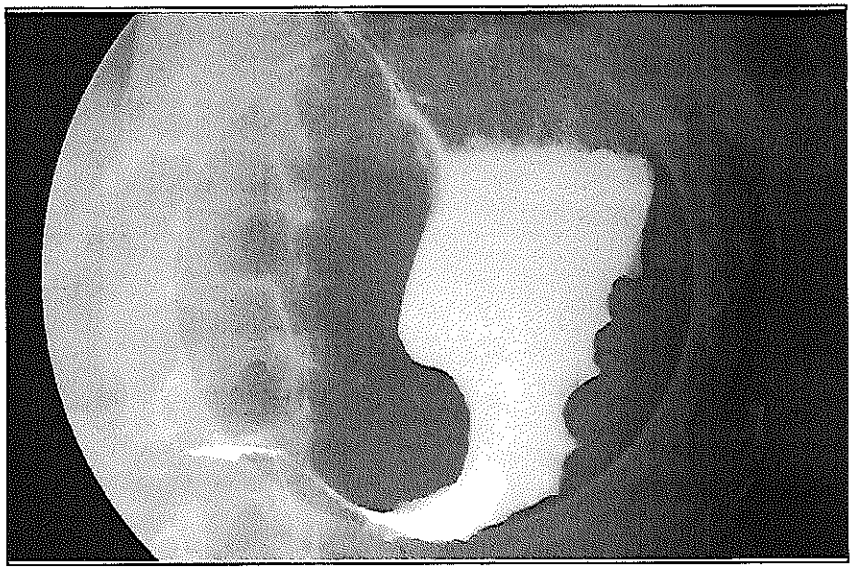

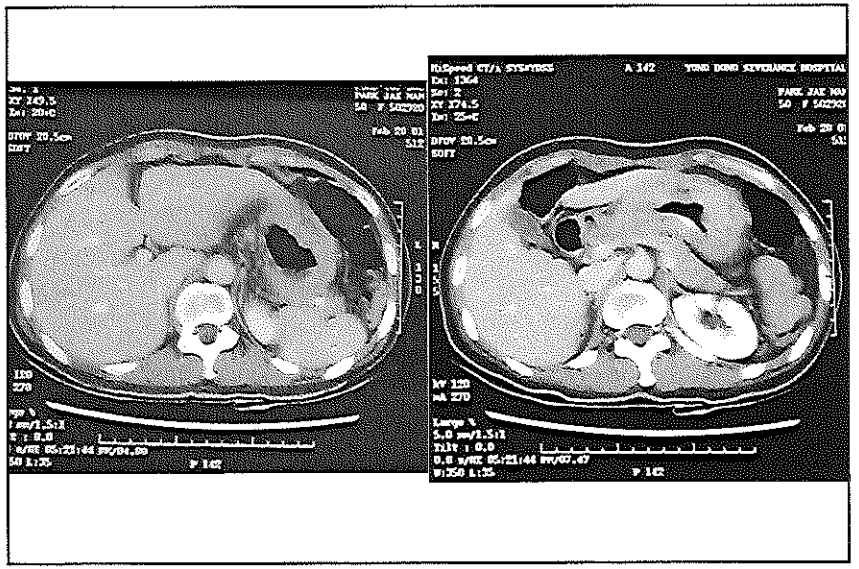

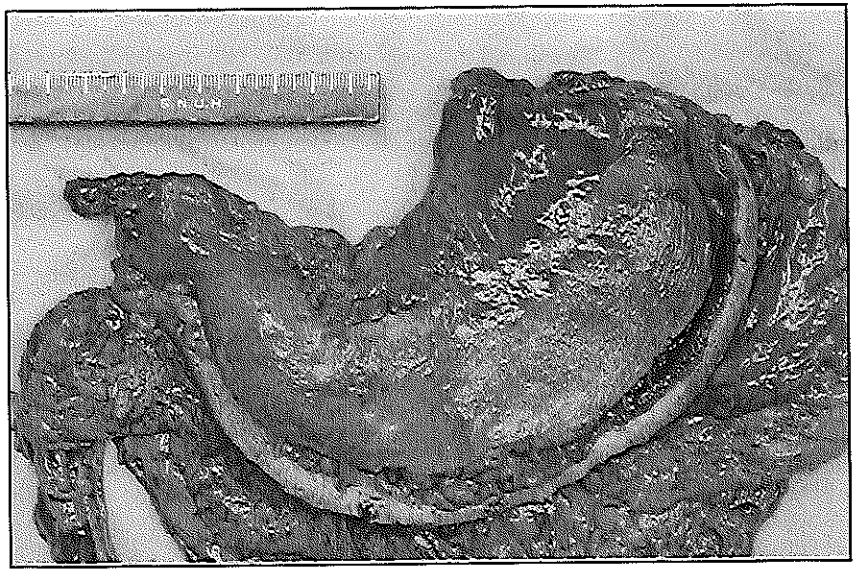

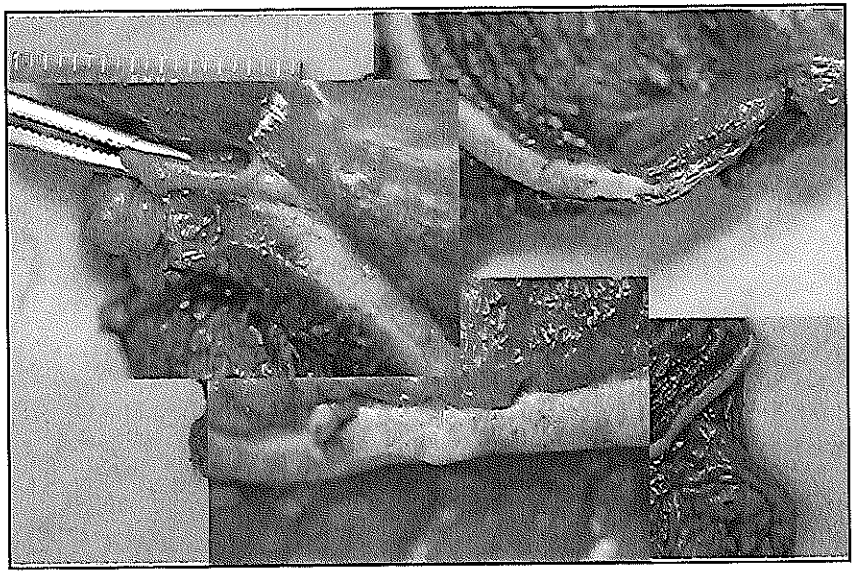

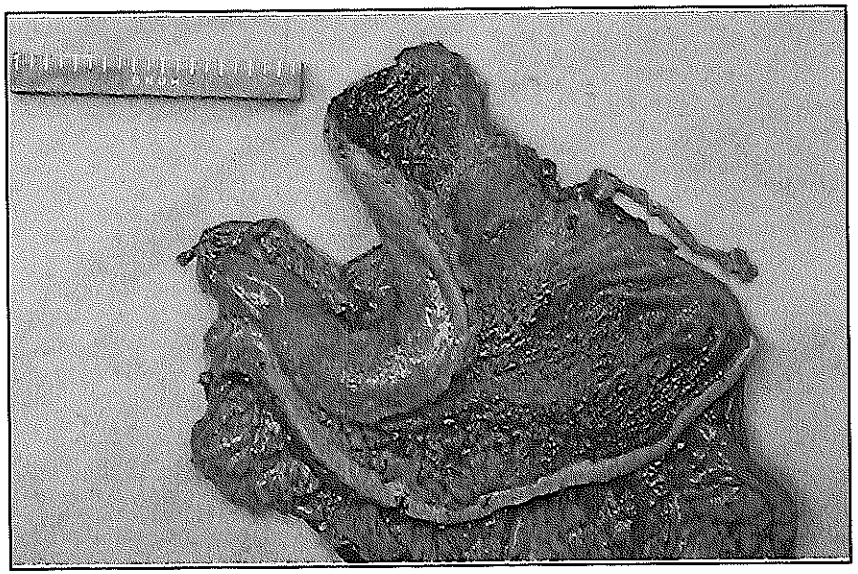

Trattamento

-Potenzialmente curativo
- -Resezione endoscopica
- -Resezione chirurgica
- -Trattamento multimodale

-Palliativo
- -Trattamento endoscopico
- -Chirurgia di by-pass
- -CHT

Resezione endoscopica

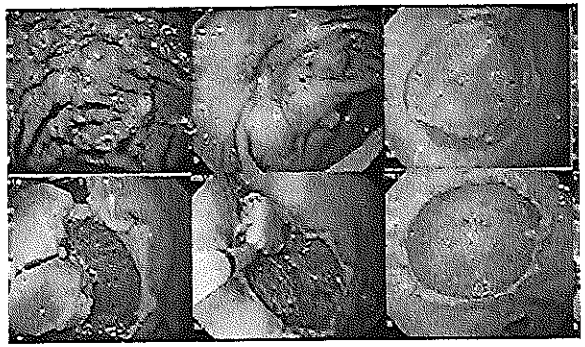

Entità della resezione gastrica

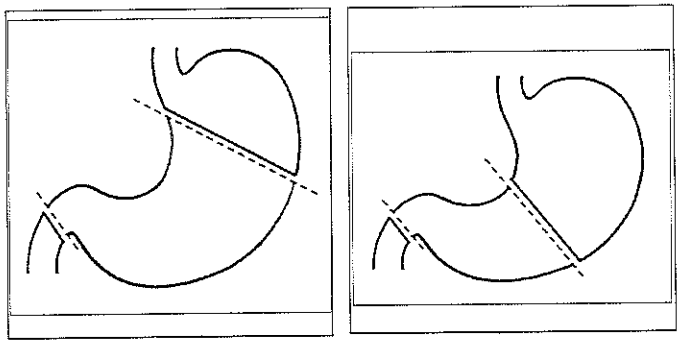

Ricostruzione



GST Tubo digerente III gpo

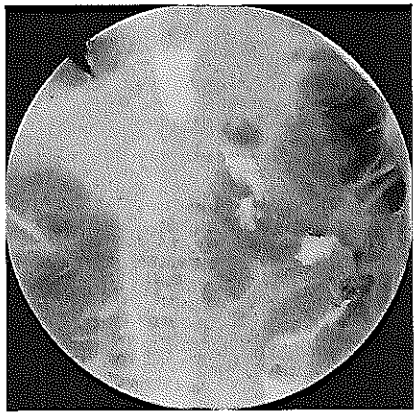

Gastrectomia Totale

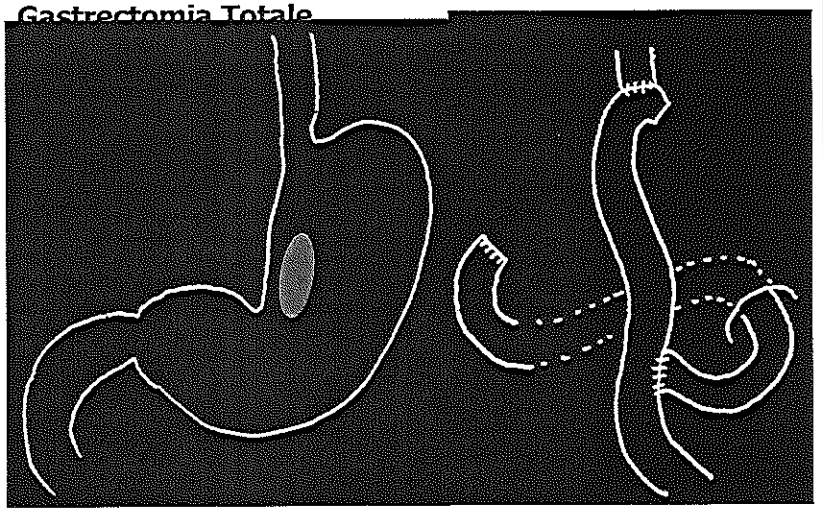

Entità della resezione linfonodale

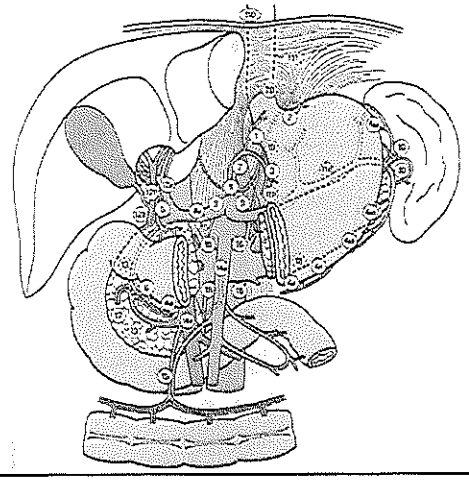

By pass palliativo

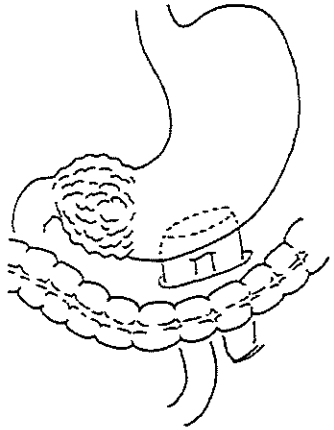

GEA Tubo digerente VI gpo

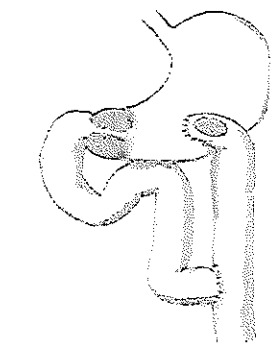

FIGURE 2 - Roux-en-Y gastroenteroanastomosis

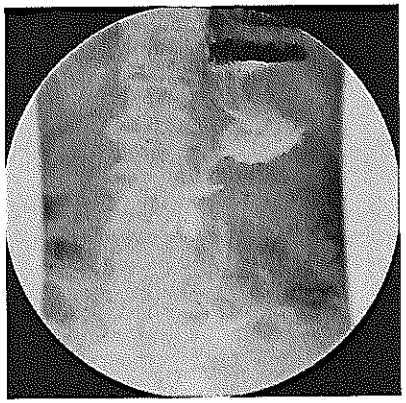

Recidiva dopo chirurgia

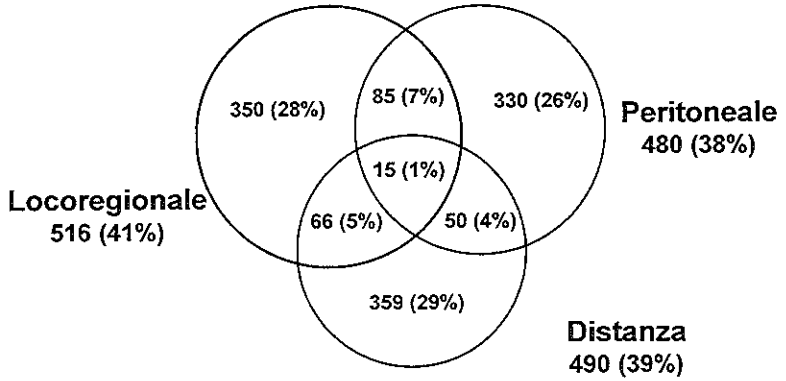

Adenocarcinoma del Giunto esofago-Gastrico

INTRODUZIONE

Classificazione sec. Siewert

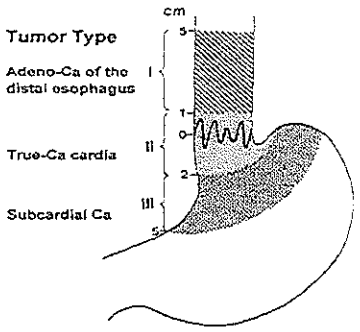

INTRODUZIONE

Tipo II sec. Siewert

Aetiology and classification of adenocarcinoma of the gastro-oesophageal junction/cardia

Kenneth E L McColl,[1] James J Going[2]

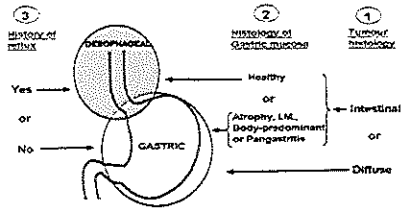

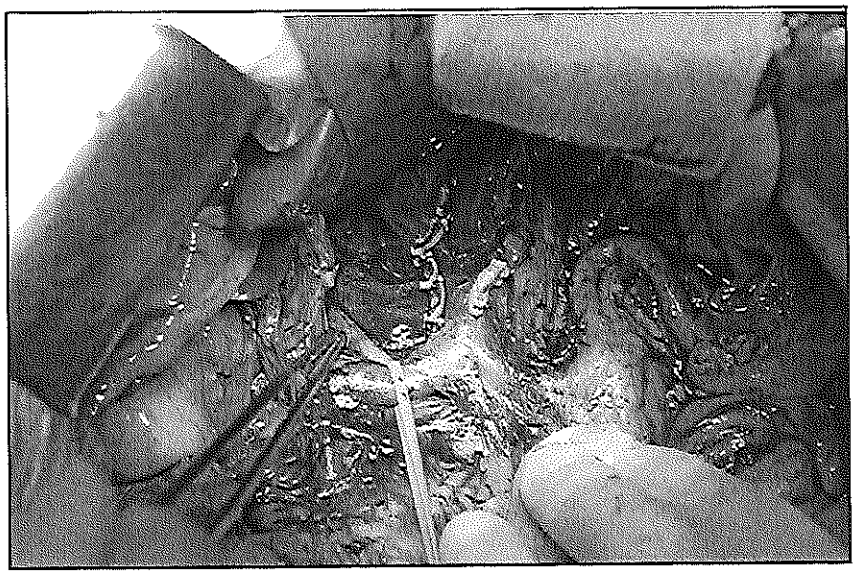

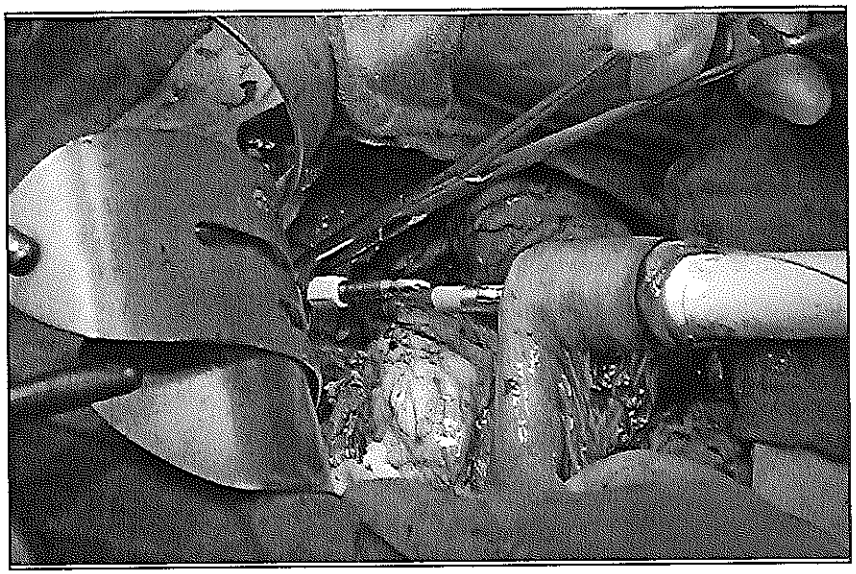



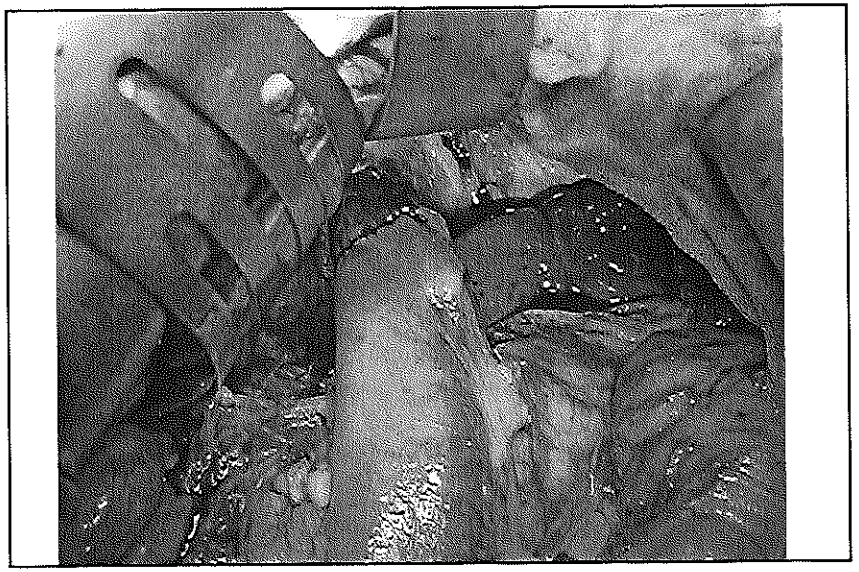

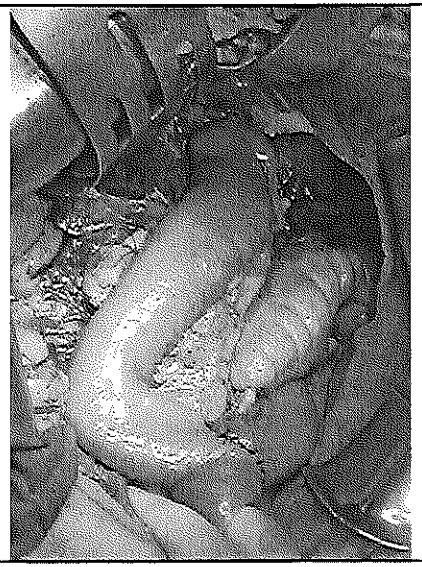

Caso Clinico 1

M, 83 anni, fumatore

Disfagia ingravescente, vomito alimentare e

calo ponderale di 5 kg in 3 mesi

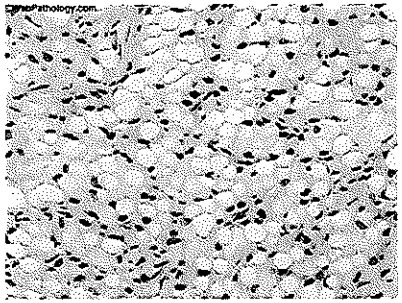

CEA: 4 mcg/L, CA 19-9: 25 U/mL

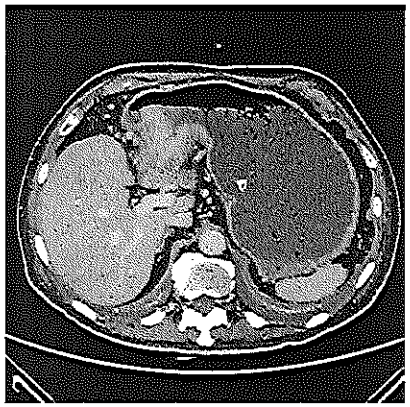

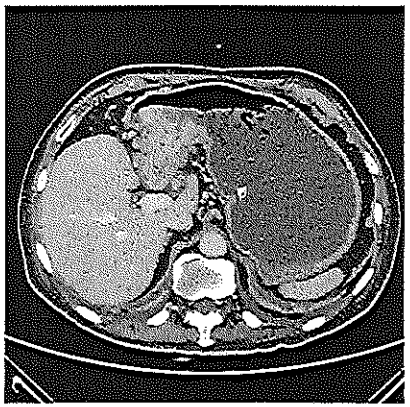

?

Caso Clinico 2

M, 67 anni, fumatore, bevitore

Precedente intervento ORL + RT per SCC corda vocale falsa

Disfagia ai solidi e calo ponderale di 7 kg in 6 mesi

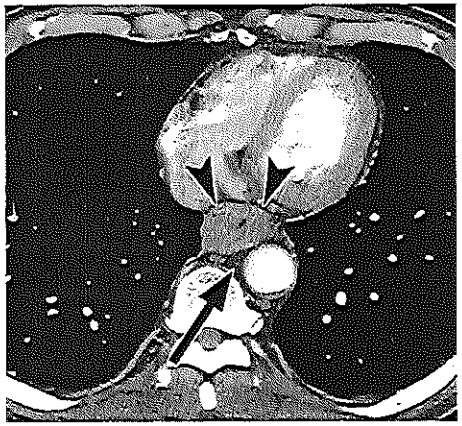

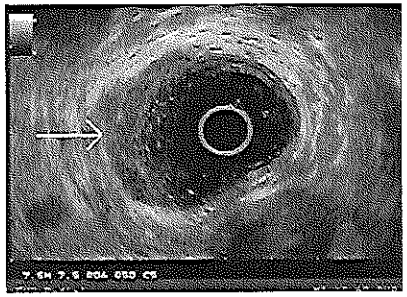

-PET TC negativa

-TBS negativa

-CEA e CA 19-9 negativi

Child A

FEV1: 2.1 L

?

Caso Clinico 3

M, 56 anni, BMI 27

Storia di GERD da 10 anni peggiorato da 2 e trattato con IPP e antiacidi

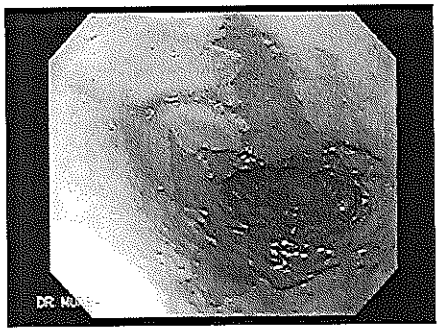

Metaplasia intestinale con displasia severa

?

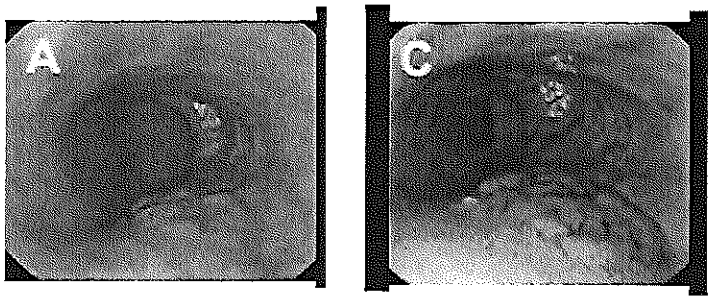

Metaplasia intestinale con displasia severa

?

Caso Clinico 3b

M, 56 anni, BMI 27
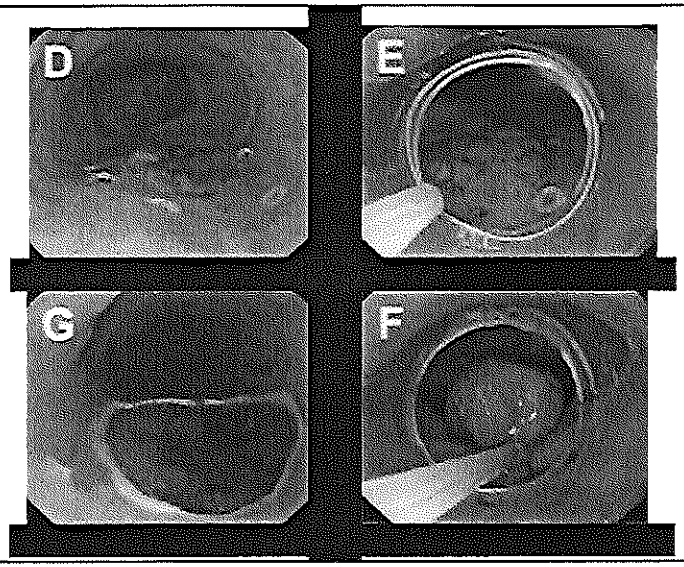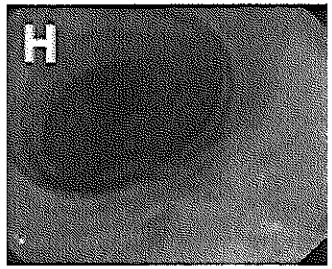
Storia di GERD da 10 anni peggiorato da 2 e trattato con IPP e antiacidi